

Angiomatoid Fibrous Histiocytoma (AFH)

Identity

Other names Angiomatoid malignant fibrous histiocytoma (AMFH)

Classification

Note Angiomatoid fibrous histiocytoma is a rare soft tissue tumor of low-grade malignancy that usually occurs in children and young adults. Eighty-eight percent of patients are 30 years of age or younger. Enzinger in 1979 first designated the tumor as angiomatoid malignant fibrous histiocytoma. The tumour was later renamed angiomatoid fibrous histiocytoma because of its slow growth and rare metastasis. This tumor forms solid, lobulated sheets of plump to spindled cells having histiocytic features adjacent to areas of haemorrhage.

Clinics and Pathology

Note This tumour typically affects children and young adults, presenting as a painless, slowly growing subcutaneous soft tissue mass that is usually located in the extremities and less commonly in the trunk, head, and neck. Only 18% of reported cases involved deep structures, such as skeletal muscle or periosteum.

Disease Symptoms of anemia, weight loss, and fever are observed in a minority of cases; local symptoms, such as pain or tenderness, are extremely rare.

Embryonic origin Symptoms of anemia, weight loss, and fever are observed in a minority of cases; local symptoms, such as pain or tenderness, are extremely rare.

Clinics Clinically, the tumor is often mistaken for hematoma or hemangioma. The diagnosis of angiomatoid fibrous histiocytoma is made on the basis of histopathology and immunohistochemical studies. Three microscopic findings are characteristic of AFH: (1) solid arrays or nests of histiocyte-like cells, (2) hemorrhagic cyst-like spaces, and (3) aggregates of chronic inflammatory cells. Multifocal recent and old hemorrhages are a striking feature in this tumor. These spaces resemble vascular spaces, but they are not lined by endothelium. Inflammatory cells present include lymphocytes and plasma cells. A thick pseudocapsule and occasional germinal centers give this tumor a resemblance to a lymph node. Immunohistochemical studies are helpful in differential diagnosis of AFH. It was reported that the histiocytic marker CD68 was positive in 9 of 19 (47%) cases of angiomatoid fibrous histiocytoma.

Immunopositivity for myoid or myofibroblastic markers in more than 50% of cases has also been reported.

Treatment Local recurrence has been reported in 11% of patients and distant metastasis in 1%; wide excision is recommended as the treatment of angiomatoid fibrous histiocytoma. Local recurrence is attributed to the infiltrative margin and deep location of the tumour. Angiomatoid fibrous histiocytoma in the head and neck also can frequently recur, which may be a result of the difficulty of performing a wide local excision. If the tumor is unresectable or has metastasized, adjuvant chemotherapy may be helpful.

Cytogenetics

Note This disease is characterised by the translocations: t(12;16) (q13;p11) and t(12;22)(q13;q12).

Cytogenetics FUS-ATF1 fusion gene in the t(12;16)(q13; p11).

Molecular EWSR1-ATF1 fusion gene in the t(12;22)(q13;q12)

Genes involved and Proteins

Gene Name [FUS \(TLS\)](#)

Location 16p11

Dna / Rna FUS gene consists of 15 exons located within 11 kb of genomic DNA.

Protein FUS protein, provisionally designated TLS (translocated in liposarcoma), and then called FUS, contains an RNA-recognition motif and is a component of nuclear riboprotein complexes. Lack of FUS in mice causes lethality into neonatal period, it influences lymphocyte development in a non-cell-intrinsic manner, it has an intrinsic role in the proliferative responses of B cells to specific mitogenic stimuli, and it is required for the maintenance of genomic stability. The involvement of a nuclear riboprotein in these processes in vivo indicates that FUS is important in genome maintenance.

Somatic mutation FUS has been also shown a partner of gene fusions linked in other malignancies: fused to ERG in acute myeloid leukaemia with t(16;21) (p11;q22), fused to [CREB3L2](#) in low-grade fibromyxoid sarcoma (LGFMS) by a translocation between chromosome bands 7q33-q34 (CREB3L2) and 16p11 (FUS), fused to ATF1 in histiocytoma or fused to CHOP gene in Myxoid Liposarcoma with t(13;16)(q13;p11).

Gene Name [ATF1](#)

Location 12q13

Dna / Rna 816 bp mRNA

Protein ATF1 gene encodes a member of the CREB-ATF basic leucine-zipper (bZIP) family of transcription factors. This protein of 271 amino acids has a nuclear localization. Function: DNA binding protein, binds the

consensus sequence: 5'GTGACGT (A/C) (A/G)-3'; cAMP-inducible transcription factor (cAMP-responsive enhancer-binding protein (CRE), like CREB. Is a member of the CREB protein family.

Somatic mutation t(12;22)(q13;q12) in Angiomatoid Fibrous histiocytoma ATF1-EWSR1. It is also rearranged in clear cell sarcoma (CCS) with t(12;22) (q13;q12), creating an EWSR1-ATF1 fusion gene.

Gene Name [EWSR1](#)

Location 22q12

Dna / Rna DNA spans over 40 kb; open reading frame: 2.0 kb, 17 exons. Transcription 2.4 kb mRNA; centromere to telomere direction; differential splicing

Protein 656 amino acids; serine-tyrosine tandem repeats. It has a wide expression and functions as a RNA binding.

Somatic mutation Ewing tumours with: t(11;22)(q24;q12) --> [FLI1](#) - EWSR1. Ewing tumours: including Ewing's Sarcoma and peripheral primitive neuroectodermal tumour.

Ewing tumours with t(21; 22)(q21;q12) --> [ERG](#) - EWSR1. Ewing tumours (Ewing's Sarcoma and peripheral primitive neuroectodermal tumour).

Ewing tumours with t(7;22)(p22;q12) --> [ETV1](#) - EWSR1. Ewing tumours ([Ewing's Sarcoma and peripheral primitive neuroectodermal tumour](#)).

Ewing tumours with t(17;22)(q12;q12) --> [E1AF](#) - EWSR1. Ewing tumours (Ewing's Sarcoma and peripheral primitive neuroectodermal tumour).

t(11;22)(p13;q12) / [Intra abdominal desmoplastic small round cell sarcoma](#) (IADSRCT) --> [WT1](#) - EWSR1.

t(12;22)(q13;q12) / Angiomatoid Fibrous Histiocytoma --> ATF1 - EWSR1.

[t\(9;22\)\(q22;q12\) / Myxoid Chondrosarcoma](#) --> [TEC](#) - EWSR1

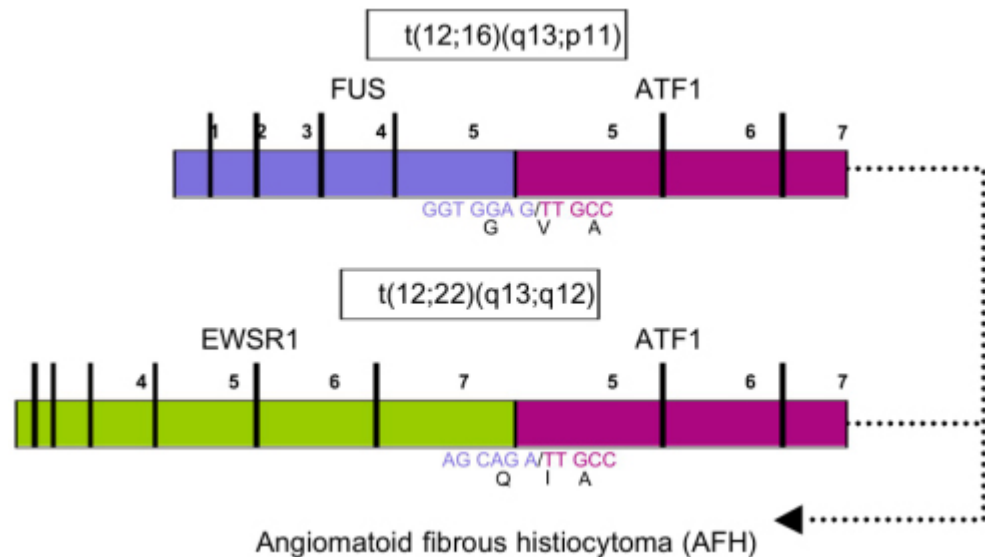
Result of the chromosomal anomaly

Hybrid Gene

Description FUS-ATF1 fusion gene t(12;16)(q13;p11).
EWSR1-ATF1 fusion gene t(12;22)(q13;q12)

Fusion Protein

Note FUS/ATF-1



Description This fusion was generated by a translocation between chromosomal bands 16p11 and 12q 13, harbouring the FUS and ATF1 genes, respectively. FUS is interrupted at codon 175 (exon5) and fused to codon 110 (exon 5) of ATF1, resulting in an in-frame junction with a glycine to valine (GGT to GTT) transition.

Description The fusion gene contains the N-terminus of FUS and the DNA binding domain of ATF-1 with a glycine to valine transition at the junction. This is similar to the EWS/ATF1 chimeric protein found in [CCS \(clear cell sarcoma\)](#).
The normal ATF1 gene is transcribed from centromere to telomere, while the transcription of FUS seems to proceed in the opposite direction. Hence, the formation of FUS/ATF-1 is possible only if another genomic aberration, such as an inversion, occurs in addition to the chromosomal translocation. Such an event would be analogous to the formation of EWS/[ERG](#) in [Ewing sarcoma](#) and EWS/[CHOP](#) in [myxoid liposarcoma](#).

Fusion Protein

Note EWSR1-ATF1

Description See the diagram above. EWSR1 is interrupted at codon 265 (exon 7) and fused to codon 110 (exon 5) of ATF-1, resulting in an in-frame junction. The chimaeric protein is composed of the N-terminal domain of EWS linked to the bZIP domain of ATF-1.

Description The fusion gene EWSR1-ATF1 can be associated with different tumor types (Clear cell sarcoma (CCS) and Angiomatoid fibrous histiocytoma (AFH)). Activation of the EWSR1-ATF1 oncogene is probably an early step in the transformation process, but the overall gene expression patterns are likely to vary considerably between AFH and CCS, in keeping with their clinopathologic differences.

EWS/ATF1 functions as a potent constitutive activator of several cAMP-

inducible promoters when assayed by transfection in cells lacking EWS/ATF1.

EWSR1 like FUS is an RNA-binding protein. Both are involved as the N-terminal part of fusion proteins in a number of sarcomas in combination with various transcription factor partners suggested to be tumor-specific. It has been previously shown that the N-terminal parts of EWSR1 and FUS are fused to certain transcription factors, resulting in a common or very similar oncogenic potential having the same tumor phenotype.

Bibliography

Angiomatoid malignant fibrous histiocytoma: a distinct fibrohistiocytic tumor of children and young adults simulating a vascular neoplasm.

Enzinger FM.

Cancer 1979; 44: 2147-2157.

Medline [228836](#)

Angiomatoid malignant fibrous histiocytoma. A follow-up study of 108 cases with evaluation of possible histologic predictors of outcome.

Costa MJ and Weiss SW.

Am J Surg Pathol 1990; 14: 1126-1132.

Medline [2174650](#)

Evaluation of CD68 and other histiocytic antigens in angiomatoid malignant fibrous histiocytoma.

Smith ME, Costa MJ and Weiss SW.

Am J Surg Pathol 1991; 15: 757-763.

Medline [1676879](#)

EWS and ATF-1 gene fusion induced by t(12;22) translocation in malignant melanoma of soft parts.

Zucman J, Delattre O, Desmaze C, Epstein AL, Stenman G, Speleman F, Fletchers CD, Aurias A and Thomas G.

Nat Genet 1993; 4: 341-345.

Medline [8401579](#)

Combinatorial generation of variable fusion proteins in the Ewing family of tumours.

Zucman J, Melot T, Desmaze C, Ghysdael J, Plougastel B, Peter M, Zucker JM, Triche TJ, Sheer D, Turc-Carel C and et al.

Embo J 1993; 12: 4481-4487.

Medline [8223458](#)

EWS-erg and EWS-Fli1 fusion transcripts in Ewing's sarcoma and primitive neuroectodermal tumors with variant translocations.

Giovannini M, Biegel JA, Serra M, Wang JY, Wei YH, Nycum L, Emanuel BS and Evans GA.

J Clin Invest 1994; 94: 489-496.

Medline [8040301](#)

An RNA-binding protein gene, TLS/FUS, is fused to ERG in human myeloid leukemia with t(16;21) chromosomal translocation.

Ichikawa H, Shimizu K, Hayashi Y and Ohki M.

Cancer Res 1994; 54: 2865-2868.

Medline [8187069](#)

A second Ewing's sarcoma translocation, t(21;22), fuses the EWS gene to another ETS-family transcription factor, ERG.

Sorensen PH, Lessnick SL, Lopez-Terrada D, Liu XF, Triche TJ and Denny CT.

Nat Genet 1994; 6: 146-151.

Medline [8162068](#)

Fusion of the EWS and CHOP genes in myxoid liposarcoma.

Panagopoulos I, Hoglund M, Mertens F, Mandahl N, Mitelman F and Aman P.

Oncogene 1996; 12: 489-494.

Medline [8637704](#)

Additional evidence of a variant translocation t(12;22) with EWS/CHOP fusion in myxoid liposarcoma: clinicopathological features.

Dal Cin P, Sciot R, Panagopoulos I, Aman P, Samson I, Mandahl N, Mitelman F, Van den Berghe H and Fletcher CD.

J Pathol 1997; 182: 437-441.

Medline [9306965](#)

Angiomatoid "malignant" fibrous histiocytoma: a clinicopathologic study of 158 cases and further exploration of the myoid phenotype.

Fanburg-Smith JC and Miettinen M.

Hum Pathol 1999; 30: 1336-1343.

Medline [10571514](#)

Molecular genetics of chromosome translocations involving EWS and related family members.

Kim J and Pelletier J.

Physiol Genomics 1999; 1: 127-138.

Medline [11015571](#)

Angiomatoid fibrous histiocytoma: a case report and review of the literature.

Jacobs IA and Chevinsky A.

Dermatol Surg 2000; 26: 491-492.

Medline [10816241](#)

Pathologic quiz case: a large cystic thigh mass in a 10-year-old boy.

Wang H, Jafri J, Recant W and Montag AG.

Arch Pathol Lab Med 2000; 124: 783-784.

Medline [10782174](#)

Genetic characterization of angiomatoid fibrous histiocytoma identifies fusion of the FUS and ATF-1 genes induced by a chromosomal translocation involving bands 12q13 and 16p11.

Waters BL, Panagopoulos I and Allen EF.

Cancer Genet Cytogenet 2000; 121: 109-116.

Medline [11063792](#)

Angiomatoid fibrous histiocytoma in mediastinum.

Asakura S, Tezuka N, Inoue S, Kihara N and Fujino S.

Ann Thorac Surg 2001; 72: 283-285.

Medline [11465207](#)

Fusion of the FUS and ATF1 genes in a large, deep-seated angiomatoid fibrous histiocytoma.

Raddaoui E, Donner LR and Panagopoulos I.

Diagn Mol Pathol 2002; 11: 157-162.

Medline [12218455](#)

FUS/ERG gene fusions in Ewing's tumors.

Shing DC, McMullan DJ, Roberts P, Smith K, Chin SF, Nicholson J, Tillman RM, Ramani P, Cullinane C and Coleman N.

Cancer Res 2003; 63: 4568-4576.

Medline [12907633](#)

MRI of angiomatoid fibrous histiocytoma.

Li CS, Chan WP, Chen WT, Chang CP, Shih LS, Chen RC and Tu HY.

Skeletal Radiol 2004; 33: 604-608.

Medline [15258704](#)

Fusion of the EWSR1 and ATF1 genes without expression of the MITF-M transcript in angiomatoid fibrous histiocytoma.

Hallor KH, Mertens F, Jin Y, Meis-Kindblom JM, Kindblom LG, Behrendtz M, Kalen A, Mandahl N and Panagopoulos I.

Genes Chromosomes Cancer 2005; 44: 97-102.

Medline [15884099](#)

Fine-needle aspiration cytology of angiomatoid malignant fibrous histiocytoma.

Lemos MM, Karlen J and Tani E.

Diagn Cytopathol 2005; 33: 116-121.

Medline [16007669](#)

Understanding mesenchymal cancer: the liposarcoma-associated FUSDDIT3

fusion gene as a model.

Pérez-Mancera PA and Sánchez-García I.
Seminars in Cancer Biology 2005; 15: 206-214.
Medline [15826835](#)

[REVIEW articles](#) *automatic search in PubMed*
[Last year publications](#) *automatic search in PubMed*

Contributor(s)

Written 10-2005 Carolina Vicente-Dueñas, Isidro Sánchez-García

Citation

This paper should be referenced as such :

Vicente-Dueñas, Sánchez-García I . Angiomatoid Fibrous Histiocytoma (AFH).
Atlas Genet Cytogenet Oncol Haematol. October 2005 .
URL : <http://AtlasGeneticsOncology.org/Tumors/AngiomFibHistiocytID5204.html>

© *Atlas of Genetics and Cytogenetics in Oncology and Haematology*
